ResearchGate

See discussions, stats, and author profiles for this publication at: https://www.researchgate.net/publication/372646134

The effect of curcuma longa extract and significance of mordant as an alternative for eosin in H and E: A comparative study

Article in Indian Journal of Pathology and Microbiology · July 2023

DOI: 10.4103/ijpm.ijpm_70_23

CITATIONS
2

READS
653

5 authors, including:

Rubina M P
Sree Anjaneya College of Paramedical Sciences
7 PUBLICATIONS · 14 CITATIONS

SEE PROFILE

Mohammed Safeer T K
MES INSTITUTE OF PARAMEDICAL SCIENCES, PERINTHALMANNA, MALAPPURAM, KE...
5 PUBLICATIONS · 13 CITATIONS

SEE PROFILE

Riyas Basheer K.B.
Tejaswini Physiotherapy College, Mangalore, India
43 PUBLICATIONS · 43 CITATIONS

SEE PROFILE

All content following this page was uploaded by Riyas Basheer K.B. on 30 December 2023.

The user has requested enhancement of the downloaded file.

Downloaded from http://journals.lww.com/ijpm by BhDMf5ePHKav1zEoum1tQfN4a+kJLhEZgbsIHo4XMi0hCywCX1AWnYQp/IlQrHD3i3D0OdRyi7TvSFl4Cf3VC1y0abggQZXdtwnfKZBYtws= on 12/22/2023

RESEARCH ARTICLE

The effect of curcuma longa extract and significance of mordant as an alternative for eosin in H and E: A comparative study

Rubina M. P, Sukesh[1], Soumya V.[2], Mohammed Safeer T. K., Riyas Basheer K. B.[3]

Research Scholar, College of Allied Health Sciences, Srinivas University, Mangalore, Karnataka, [1]Department of Pathology, Srinivas Institute of Medical Sciences and Research Centre, Mangaluru, Karnataka, [2]Department of Pathology, KMCT College of Allied Health Sciences, Kozhikode, Kerala, [3]Department of Physiotherapy, Tejaswini Physiotherapy College, Mangalore, Karnataka, India

Address for correspondence:
Mrs. Rubina M. P, Mailembady, Nanminda, Kozhikode, 673613, Kerala, India.
E-mail: roobyrazaokmp@gmil.com

ABSTRACT

Background and Aim: Hematoxylin and Eosin (H and E) staining is a common and routine staining method used in Histopathology. In origin, Hematoxylin is natural and Eosin is a synthetic dye. Synthetic dyes are widely accepted due to its staining efficiency. However, due to synthetic and toxic properties, natural alternatives have gained importance. In this present study, Curcuma Longa rhizome (Turmeric) extract with and without mordant are examined as a natural substitute for Eosin in H and E staining. This study assessed the staining quality of Turmeric (H and T) compared to Eosin (H and E) and the significance of mordant in H and T staining. **Materials and Methods:** A comparative study is conducted in a Histopathology laboratory in a tertiary care hospital. Five tissue specimens were collected and stained with H and T with mordant, H and T without mordant, and conventional H and E stain. Two independent pathologists examined the quality of each stain. The results are graded as excellent, good, and poor. These results are statistically compared and analyzed. **Result:** Staining quality of Turmeric and Eosin are comparable to each other. At the same time, Turmeric gives yellow color instead of pink in Eosin. The result also shows that the addition of mordant in Turmeric significantly improves the staining quality. **Interpretation and Conclusion:** Turmeric with mordant can be used as an alternative stain to synthetic Eosin in H and E staining.

KEY WORDS: Eosin, H and E, H and T, natural dyes, turmeric

Access this article online
Website: www.ijpmonline.org
DOI: 10.4103/ijpm.ijpm_720_22
Quick Response Code:

Submitted: 03-Sep-2022
Revised: 26-Mar-2023
Accepted: 22-Apr-2023
Published: 26-Jul-2023

This is an open access journal, and articles are distributed under the terms of the Creative Commons Attribution-NonCommercial-ShareAlike 4.0 License, which allows others to remix, tweak, and build upon the work non-commercially, as long as appropriate credit is given and the new creations are licensed under the identical terms.

For reprints contact: WKHLRPMedknow_reprints@wolterskluwer.com

How to cite this article: Rubina MP, Sukesh, Soumya V, Safeer TK, Basheer KB. The effect of curcuma longa extract and significance of mordant as an alternative for eosin in H and E: A comparative study. Indian J Pathol Microbiol 2023;66:697-701.

INTRODUCTION

Hematoxylin and Eosin (H and E) staining is the major morphological staining method used in Histopathology, which uses two dyes: Hematoxylin and Eosin. The nuclear stain Hematoxylin is a natural dye, whereas the cytoplasmic stain Eosin is synthetic in origin. Although in the era of global warming and ecological crisis, the current global interest in using biodegradable materials and natural dyes/stains has evoked curiosity to explore its staining efficacy in various staining methods.[1] Due to the nontoxic effects, various natural dyes are used for coloring textiles, drugs, cosmetics, etc. In Histopathology, various natural dyes such as Hematoxylin, Saffron, Carmine, etc., are used in different staining methods. Purified alcoholic extract of *Curcuma Longa* (*C. Longa*) is used as a natural alternative in different staining experiments. In 2014, Sachin Kumar *et al.*[2] showed that purified ethanolic extract of *C. Longa's* staining reaction is similar to Eosin except for its intense yellow color.

C. Longa (Turmeric) is a common spice used in curries and food additives, also used as a dietary pigment. *C. Longa* contains flavonoids, which are typically polyphenolic compounds. Phenols are acidic in nature; hence, *C. Longa* has the ability to stain the basic parts of the cell.[3,4]

Downloaded from http://journals.lww.com/ijpm by BhDMf5ePHKav1zEoum1tQfN4a+kJLhEZgbsIHo4XMi0hCywCX1AWnYQp/IlQrHD3i3D0OdRyi7TvSFl4Cf3VC1y0abggQZXdtwnfKZBYtws= on 11/21/2023

synthetic dyes are efficient in their coloring property, they may cause different environmental problems and are harmful to human beings and animals. Hence, there is a need to find a safe alternative for synthetic dye.[5-7]

This study aimed to compare the staining efficacy of Turmeric with the synthetic Eosin in H and E staining and assess the effect of mordant (potassium alum) in Turmeric reagent. Cost-effectiveness is another important advantage of Turmeric compared to Eosin. As of current (March 2022) market in Kerala, India, 25 gms of Eosin yellow and Turmeric costs rupees (Rs.) 200 and Rs. 5, respectively. This market price shows that the cost of Eosin is significantly high as compared to Turmeric.

MATERIALS AND METHODS

The comparative study is conducted in the Histopathology laboratory of a Tertiary Healthcare Center in Kerala, India. Experiments are conducted after institutional ethical committee approval.

Methods of preparing turmeric stain

Initially, Turmeric pieces are dried and powdered using a blender. Fifteen gm turmeric solution is prepared by dissolving 15 gm turmeric powder in 100 mL 70% alcohol. Another solution is prepared with 70% alcohol saturated with potassium alum (mordant).[8]

Methods of preparing eosin stain

1 gm% of alcoholic Eosin is prepared by mixing 1 gm of commercially available Eosin powder with 100 mL of alcohol.

Methods of preparing harris hematoxylin stain

2.5 gm Hematoxylin is dissolved in 50 mL alcohol and 50 gm alum in 500 mL hot water. These two solutions are mixed and heated up to its boiling point. Later, we added 1.5 gm mercuric oxide and cooled it rapidly. Additional 20 mL of glacial acetic acid is added to improve the nuclear staining property of the mixture.

Staining procedure

H and E staining: The tissue sections are deparaffinized in two changes of xylene for 10 minutes each. Then, tissues are hydrated in descending grades (95%, 90%, and 50%) of alcohol and finally with water. Nuclear staining is performed in Harris Hematoxylin solution for 1 minute. After that, the sections were washed with water and differentiated in 1% acid alcohol. This is followed by bluing in running tap water and then dehydrated with 95% alcohol. The sections are counterstained with Eosin for 45 seconds and dehydrated in ascending grades of alcohol. Finally, the stained sections are cleared with xylene and mounted in Dibutylphthalate Polystyrene Xylene (DPX).[10-12]

H and T staining: Hematoxylin and Turmeric (H and T) staining was performed by the same method with 5 minutes in Turmeric instead of 45 seconds in Eosin in the abovementioned H and E staining.[8]

The study is carried out on the tissue specimens received at the Histopathology laboratory. Five types of tissue sections were considered: (i) epithelium, (ii) muscle, (iii) collagen, (iv) bone, and (v) adipose tissues. In this experiment, three sets of each tissue type are collected, one for H and E, another one for H and T, and a final set for H and T with mordant. Each set contains 20 sections of a particular tissue type.

Each set of tissue sections is stained with H and E, H and T with mordant, and H and T without mordant, separately. Two independent pathologists examined the stained smears under the microscope and evaluated the staining quality. The staining quality is assessed using the following grading criteria.[8]

Poor (P): Refers to difficulty in appreciating a particular tissue structure.

Good (G): Refers to sufficiently appreciate a particular tissue structure.

Excellent (E): Refers to fine appreciation of a particular tissue structure.

Pathologist's scores are summed up for each five tissue types and statistical significance is studied by applying Chi-square test.

RESULTS

The present study compared the staining quality of Turmeric and the impact of mordent in H and T staining with H and E staining. Each staining technique is conducted and examined on all five aforementioned tissue types. Each stained tissue section is examined by two independent pathologists. H and E staining shows blue-colored nucleus and pink-colored cytoplasm, while H and T shows blue-colored nucleus and yellow-colored cytoplasm.

Tables 1-3 depict the examined results from H and E, H and T, and H and T with mordent for collagen, muscle, epithelium, adipose, and bone tissues, respectively. Figures 1-5 represent the microscopic pictures of H and E staining and H and T with mordant staining.

DISCUSSION

Using eco-friendly natural alternatives will help to diminish the use of synthetic/artificial dyes in the laboratory. Thereby, we can

Figure 1: Microscopic image of collagen

Downloaded from http://journals.lww.com/ijpm by BhDMf5ePHKav1zEoum1tQfN4a+kJLhEZgbsIHo4XMi0hCywCX1AWnYQp/IlQrHD3i3D0OdRyi7TvSFl4Cf3VC1y0abggQZXdtwnfKZBYtws= on 1/12/2023

Table 1: Comparison of H and E and H and T staining

	Staining Method	E	G	P	Total	Chi-square	P
Collagen	H and E	20	0	0	20	60.0	<0.001
		100%	0%	0%	100%		
	H and T	0	19	1	20		
		0%	95%	5%	100%		
Muscle	H and E	16	4	0	20	65.0	<0.001
		80%	20%	0%	100%		
	H and T	0	15	5	20		
		0%	75%	25%	100%		
Epithelium	H and E	9	10	1	20	61.438	<0.001
		45%	50%	5%	100%		
	H and T	0	17	3	20		
		0%	85%	15%	100%		
Adiposet issue	H and E	10	10	0	20	60.8	<0.001
		50%	50%	0%	100%		
	H and T	0	5	15	20		
		0%	25%	75%	100%		
Bone	H and E	15	5	0	20	60.0	<0.001
		75%	25%	0%	100%		
	H and T	0	0	20	20		
		0%	0%	100%	100%		

E-Excellent, G-Good, P-Poor

Table 2: Comparison of H and E and H and T with mordent staining

	Staining Method	E	G	P	Total	Chi-square	P
Collagen	H and E	20	0	0	20	60.0	<0.001
		100%	0%	0%	100%		
	H and T with mordant	5	15	0	20		
		25%	75%	0%	100%		
Muscle	H and E	16	4	0	20	74.464	<0.001
		80%	20%	0%	100%		
	H and T with mordant	6	14	0	20		
		30%	70%	0%	100%		
Epithelium	H and E	9	10	1	20	67.778	<0.001
		45%	50%	5%	100%		
	H and T with mordant	6	14	0	20		
		30%	70%	0%	100%		
Adiposet issue	H and E	10	10	0	20	60	<0.001
		50%	50%	0%	100%		
	H and T with mordant	0	20	0	20		
		0%	100%	0%	100%		
Bone	H and E	15	5	0	20	61.2	<0.001
		75%	25%	0%	100%		
	H and T with mordant	0	18	2	20		
		0%	90%	10%	100%		

E-Excellent, G-Good, P-Poor

reduce the environmental pollution and harmful effects on living things. Although natural dyes such as Hematoxylin, Carmine, Saffron, etc., are used in different medical laboratory staining methods, the number of natural alternatives is less as compared to synthetic dyes.

Eosin is one of the most commonly used synthetic dyes in various staining methods. Eosin shows excellent staining quality and is a widely accepted cytoplasmic stain. However, Eosin has many

Figure 2: Microscopic image of muscle

Figure 3: Microscopic image of epithelium

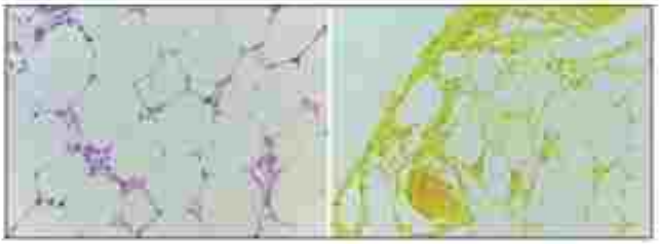

Figure 4: Microscopic image of adipose tissue

side effects; it is a skin, eye, mucus membrane irritant, and ingestion may cause nausea, headache, double vision, etc.[9-12] In Histopathology, Eosin is mainly used in combination with Hematoxylin (H and E staining). In this study, Turmeric extract is used as an alternative for Eosin in H and E staining. The staining quality of H and T with and without mordant are assessed and compared with H and E staining.

Three sets of five abovementioned tissue structures are considered to assess and compare the staining quality. Out of three sets, the first set is stained using H and T, the next using H and T with mordant, and the final set is stained using H and E staining techniques. Each set contains 100 tissue sections that include 20 sections of specific tissue types. Two independent pathologists performed the microscopic examination of these stained tissue sections. The staining quality is assessed and graded as Excellent, Good, or Poor. The agreement between two pathologist's observations is statistically strong. The grades from both pathologists are summed up, and pairwise comparison of different staining method is performed. The *P* value is <.001 for each comparison. The statistical analysis is performed using Chi-square test. The calculated results are used to compare Turmeric's staining quality with Eosin (refer Tables 1-3).

The result shows that Turmeric stains the tissue structures similar to that of Eosin. Turmeric imparts yellow color instead

Table 3: Comparison of H and T with and without mordant staining

	Staining Method	E	G	P	Total	Chi-square	P
Collagen	H and T	0	19	1	20	69.474	<0.001
		0%	95%	5%	100%		
	H and T with mordant	5	15	0	20		
		25%	75%	0%	100%		
Muscle	H and T	0	15	5	20	60.952	<0.001
		0%	75%	25%	100%		
	H and T with mordant	6	14	0	20		
		30%	70%	0%	100%		
Epithelium	H and T	0	17	3	20	60.056	<0.001
		0%	85%	15%	100%		
	H and T with mordant	6	14	0	20		
		30%	70%	0%	100%		
Adiposet issue	H and T	0	5	15	20	60	<0.001
		0%	25%	75%	100%		
	H and T with mordant	0	20	0	20		
		0%	100%	0%	100%		
Bone	H and T	0	0	20	20	60.0	<0.001
		0%	0%	100%	100%		
	H and T with mordant	0	18	2	20		
		0%	90%	10%	100%		

E-Excellent, G-Good, P-Poor

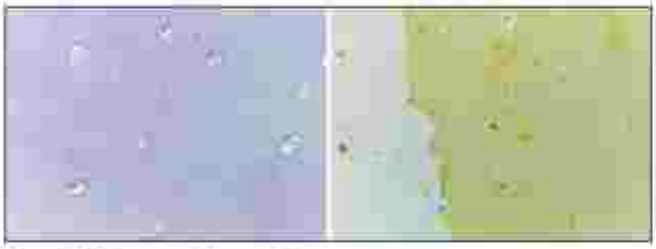

Figure 5: Microscopic image of bone

of pink by Eosin. Two types of Turmeric reagent were used in H and T staining: (i) Turmeric with mordant and (ii) Turmeric without mordant. Turmeric incorporated with mordant shows better staining quality than Turmeric without mordant. When Turmeric is used alone, the stain gets washed out during the final dehydration and clearing step. This wash-out problem may lead to fading of cytoplasmic stain. Mordant (potassium alum) increases dye adherence with the tissue structure and reduces the loss of stain during the final steps. Hence, the addition of mordant enhances the staining quality.

Among the five tissue types, collagen, muscle, and epithelium show more quality staining when compared to adipose tissue and bone. In collagen, muscle, and epithelium, 25% to 30% tissue sections show excellent staining quality in H and T staining with mordant, whereas in H and T stain without mordant, majority of the tissue sections are graded good and few of the epithelium sections show poor staining quality. Majority of the tissue sections stained with H and E show excellent staining quality.

In adipose tissue, 50% of the tissue sections show excellent and remaining 50% show good staining quality with H and E staining. Hundred percent tissue sections are graded good in H and T with mordant staining. Whereas in H and T without mordant, only 25% show good scores.

In case of bone, 75% show excellent staining quality with H and E staining. H and T staining with mordant shows good quality staining in more than 80% tissue sections, whereas Turmeric without mordant stains poorly.

Earlier studies show that many natural alternatives can be used as a cytoplasmic stain instead of Eosin. A similar study conducted by Suryawanshi *et al*[14] shows that Curcuma longa extract (Haldi) can be used as a safe, eco-friendly natural cytoplasmic stain. They emphasized the importance of Haldi in terms of its cost and availability. They concluded that Haldi could be an effective, eco-friendly, and safe substitute for Eosin, an expensive synthetic dye compared to Haldi. They also found that although Eosin is the most efficient counterstain for Hematoxylin, Turmeric can also be used as an adequate substitute for Eosin.

Abraham *et al*[15] compared the staining efficacy of Turmeric and Eosin using two different extraction methods. For Turmeric, they used maceration and soxhlet extraction methods. In these methods, tissue sections stained using the maceration technique show better staining than the soxhlet method. Using these results, they concluded that turmeric extract could be used as an efficient cytoplasmic stain instead of Eosin.

A similar study conducted by Rubina *et al*[16] used 15 gm Turmeric in 70% alcohol in place of Eosin in H and E staining. They concluded that although Eosin is a widely accepted cytoplasmic dye, but due to its synthetic effect, Turmeric can be used as a safe natural alternative.

Apart from Turmeric, many other natural alternatives such as Ginger, Hibiscus, Cola nut, and Santan flower, etc., are experimented as substitutes for synthetic dyes.[17-19] In 2018, Sudhakaran *et al*[20] conducted a similar study using Ginger (*Zingiber officinale Roscoe*) extract. They also compared the staining quality of Ginger with Curcumin. The results indicate that both dyes stain the cytoplasm and Ginger shows better reaction than Curcumin. Similarly, they also compared the shelf life of Ginger with Curcumin. The study shows that Ginger extract has more shelf life than Curcumin.

CONCLUSION

Artificial/synthetic agents are widely used in various fields for different experiments and applications. Medical laboratories are one of the best examples of these synthetic agent's usage. Various chemicals and dyes are used in laboratories for diagnostic purposes. In performance, they show high quality, but on the other hand, these chemicals are one of the major reasons for global warming and many ecological problems. Among these various dyes, we considered Eosin, a major synthetic dye used in Histopathology. Eosin is one of the best cytoplasmic stains and is used in combination with H and E. In this study, we used

Downloaded from http://journals.lww.com/ijpm by BhDMf5ePHKav1zEoum1tQfN4a+kJLhEZgbsIHo4XMi0hCywCX1AWnYQp/IlQrHD3i3D0OdRyi7TvSFl4Cf3VC1y0abggQZXdtwnfKZBYtws= on 11/21/2023

Turmeric (with and without mordant) in place of Eosin in H and E staining. Comparing the staining quality with Eosin, Turmeric shows a similar result except for the yellow coloration instead of pink. Incorporation of mordant with Turmeric improves the staining quality over Turmeric. The experimental results and discussion conclude that although Eosin shows better staining quality, considering the harmful effect of synthetic dyes (Eosin), Turmeric can be used as an efficient natural, safe, eco-friendly, and cost-effective substitute for Eosin.

Financial support and sponsorship
Nil.

Conflicts of interest
There are no conflicts of interest.

REFERENCES

1. Abraham M, Nambiar S, Charagannavar V, Augustine D, Sowmya SV, Babu A, et al. Comparison of staining efficacy between turmeric and eosin: A histological study. J Clin Diagn Res 2017;11:ZC05-8.
2. Kumar S, Singh NN, Singh A, Singh N, Sinha RK. Use of curcuma longa l. extract to stain various tissue samples for histological studies. Ayu 2014;35:447-51.
3. Akwiboto O, Omwuka S, Moody J, Agbedahunsi JM, Oduola T, Ekpo OE, et al. Curcuma longa extract as a histological dye for collagen fibres and red blood cells. J Anat 2007;210:600-3.
4. Suryawanshi H, Naik R, Kumar P, Gupta R. Curcuma longa extract-haldi: A safe, eco-friendly natural cytoplasmic stain. J Oral Maxillofac Pathol 2017;21:340-4.
5. Bondoc CC. Curcuma longa linn rhizome extract as an alternative stain for histological studies. J Pharmacogn Phytochem 2018;7:2010-7.
6. Bordoloi B, Jaiswal R, Siddiqui S, Tandon A. Health hazards of special stains. Saudi J Pathol Microbiol 2017;2:175-8.
7. Bassey RB, Oremosu AA, Osinubi A. Curcuma longa: Staining effect on histomorphology of the testes. Maced J Med Sci 2012;5:26-9.
8. Ramamoorthy A, Ravi S, Jeddy N, Thangavelu R, Janardhanan S. Natural alternatives for chemicals used in histopathology lab-A literature review. J Clin Diagn Res 2016;10:EE01-4.
9. Rubina M, Krishnan AM, Riyas Basheer K, Mohammed ST, Soumya Y. Assessment of staining quality of curcumin as a substitute for eosin in hematoxylin and eosin staining in histopathology. J Res Med Dent Sci 2020;8:146-50.
10. Culling CFA, Allison R, Barr W. Demonstration Methods. Cellular Pathology Technique. Butterworth: Elsevier; 2014. p. 154-63.
11. Mukunda A, Narayan T, Shreedhar B, Shashidhara R, Mohanty L, Shenoy S. Accelerated staining technique using kitchen microwave oven. Indian J Pathol Microbiol 2015;58:216-22.
12. Aydin I, Yörükoglu K, Cingöz S, Agilkaya S. The effect of the alternative solutions to formaldehyde and xylene on tissue processing. Indian J Pathol Microbiol 2013;56:221-30.
13. Hope-Roberts M, Horobin R. A review of curcumin as a biological stain and as a self-visualizing pharmaceutical agent. Biotech Histochem 2017;92:319-23.
14. Sudhakaran A, Hellikeri K, Babu B. Natural stains zingiber officinale roscoe (ginger) and curcuma longa l. (turmeric)–a substitute to eosin. Ayu 2018;39:220-6.
15. Agbede M, Benard S, Afolabi O, Okoye JO, Bankole JK, Fowotade AA, et al. The use of hibiscus sabdariffa extract as nuclear stain for skin morphology and connective tissue with eosin counterstain. Sokoto J Med Lab Sci 2017;2:28-32.
16. Sridhara SU, Raju S, Gopalkrishna AH, Haragannavar VC, Latha D, Mirshad R. Hibiscus: A different hue in histopathology. J Med Radiol Pathol Surg 2016;2:9-11.
17. Chinyere C, Etoforinini C. Alternative staining of kidney tissue sections with extracts of turmeric (curcuma longa) and zobo (hibiscus sabdariffa). J Histotechnol 2017;1-9.
18. Bose S, Sharma M, Karthikeyan R, Kumar M, Chawla C, Tyagi V. A histopathological correlative assessment of cytoplasmic staining by aqueous extracts of hibiscus and turmeric with eosin on tissue samples. Int J Health Sci 2022;6:2915-25.
19. Ibnouf AA, AbdulRaheem E, SeedAhmed M, Dahab D. Assessment of staining quality of roselle (hibiscus sabdariffa) on formalinfixed paraffin-embedded renal tissue sections. Int J Curr Res Rev 2014;6:26-8.
20. Kuspulu N. Dual staining effect of extracts roselle (hibiscus sabdariffa l.) and red cabbage (brassica oleracea) on wistar rat tissues. 2021. doi: 10.21203/rs. 3.rs-214239/v1.
21. Cruz PEC, De Vera AP, Villa ADM. The efficacy of santan flower (ixora coccinea linn.) as an alternative stain to eosin y in Wright-Giemsa stain. Lyceum Philippines St Cabrini J Allied Med 2018;3:1-1.
22. Shehu SA, Sonfada M, Danmaigoro A, Umar AA, Hena SA, Wiam IM. Kola nut (cola acuminata) extract as a substitute to histological tissue stain eosin. Sci J Vet Adv 2012;1:33-7.
23. Meenakshi, Savana S, Sundaragiri KS, Sankhla B, Bhargava A, Rawat M. A comparative cytological study of Eosin & eco-friendly cytoplasmic stains-A pilot study. IOSR J Dent Med Sci 2021;20:44-9.

Downloaded from http://journals.lww.com/ijpm by BhDMf5ePHKav1zEoum1tQfN4a+kJLhEZgbsIHo4XMi0hCywCX1AWnYQp/IlQrHD3i3D0OdRyi7TvSFl4Cf3VC1y0abggQZXdtwnfKZBYtws= on 10/21/2021